

Reconstructive treatment of peri-implant defects—Results after three and five years

Ahmad Aghazadeh¹ | G. Rutger Persson^{2,3}  | Andreas Stavropoulos^{4,5}  | Stefan Renvert^{2,6,7} 

¹Tand & Implantat Specialistkliniken, Solna, Sweden

²Department of Oral Sciences, Kristianstad University, Kristianstad, Sweden

³Department of Periodontics and Oral Medicine, University of Washington, Seattle, WA, USA

⁴Department of Periodontology, Malmö University, Malmö, Sweden

⁵Division of Regenerative Dental Medicine and Periodontology, CUMD, University of Geneva, Geneva, Switzerland

⁶Blekinge Institute of Technology, Karlskrona, Sweden

⁷Faculty of Dentistry, The University of Hong Kong, Hong Kong, SAR, China

Correspondence

Stefan Renvert, Oral Health Sciences, Kristianstad University, Kristianstad 291 88, Sweden.

Email: stefan.renvert@hkr.se

Funding information

Högskolan Kristianstad

Abstract

Objectives: The aim of this study was to assess the long-term efficacy of reconstructive treatment of peri-implantitis intraosseous defects.

Material and Methods: Peri-implant intraosseous defects were augmented using either an autogenous bone graft (AB) or a bovine-derived xenograft (BDX) in combination with a collagen membrane. Maintenance was provided every third month.

Results: In the AB group, 16 patients with 25 implants remained at year five. In the BDX group, 23 patients with 38 implants remained. Between baseline and year 5, bleeding on probing (BOP) and probing pocket depth (PPD) scores were reduced in both groups ($p < .001$). In the AB and BDX groups, mean PPD between baseline and year five was reduced by 1.7 and 2.8 mm, respectively. The difference between groups was significant ($p < .001$). In the AB group, the mean bone level change at implant level between baseline and years three and five was -0.2 and -0.7 mm, respectively. In the BDX group, the mean bone level change at implant level between baseline and years three and five was 1.6 and 1.6 mm, respectively. The difference between the groups was significant ($p < .001$). Successful treatment (no bone loss, no probing pocket depth (PPD) > 5 mm, no suppuration, maximum one implant surface with bleeding on probing (BOP) at year five) was obtained in 9/25 implants (36%) in the AB group and in 29/37 implants (78.3%) in the BDX group.

Conclusions: Reconstructive surgical treatment of peri-implant defects using BDX resulted in more predictable outcomes than using autogenous bone over 5 years.

KEYWORDS

bone augmentation, peri-implantitis, reconstructive surgery

1 | INTRODUCTION

Peri-implantitis is a complication following implant therapy affecting soft and hard tissues around dental implants (Berglundh et al., 2018). In a recent systematic review and meta-analysis, the estimated weighted mean prevalence of peri-implantitis at

a patient level was reported to be 22% (CI: 14%–30%) (Derks & Tomasi, 2015). Due to significant heterogeneity in case definitions, peri-implantitis prevalence in the included individual studies varied between 1% and 47%. Treatment of peri-implantitis is difficult and complex. The surface structure and implant threads make assessing and removing the biofilm and hard deposits difficult.

This is an open access article under the terms of the [Creative Commons Attribution-NonCommercial-NoDerivs](https://creativecommons.org/licenses/by-nc-nd/4.0/) License, which permits use and distribution in any medium, provided the original work is properly cited, the use is non-commercial and no modifications or adaptations are made.

© 2022 The Authors. *Clinical Oral Implants Research* published by John Wiley & Sons Ltd.

Non-surgical treatment modalities may not result in healthy conditions (Renvert, Roos-Jansåker, Claffey, 2008). In clinical practice, surgical intervention is often used to expose and debride the contaminated part of the implant surface. Reconstructive surgical treatment of peri-implantitis defects aims to obtain a healthy situation at the implant following therapy and to reconstruct the lost bone support. Different graft materials (allografts, autografts, xenografts, material derived from corals and titanium granules) have been used alone or in combination with different types of membranes, or adjunctive antibiotics have demonstrated short-term improvements (Roos-Jansåker, Renvert, Lindahl, Renvert., 2007, Aghazadeh, Person, Renvert., 2012, Jepsen et al., 2016, Rocuzzo, Gaudio, Lungo, Dalmaso., 2016, Renvert, Roos-Jansåker, Persson., 2018, Mercado, Hamlet, Ivanovski., 2018, Nart, de Tapia, Pujol, Pascual, Valles., 2018, Clem & Gunsolley., 2019). Data on long-term treatment outcomes following reconstructive surgical therapy of peri-implantitis defects are, however, limited (Rocuzzo, Fierravanti, Pittoni, Dalmaso, Rocuzzo., 2020; Mercado, Hamlet, Ivanovski., 2018; Rocuzzo, Pittoni, Rocuzzo, Charrier, Dalmaso., 2017; Roos-Jansåker et al. 2014; Schwarz, Sahm Bieling, Becker, 2009). Regular supportive care is considered essential to retain and secure long-term results (Heitz-Mayfield et al. 2018; Rocuzzo, Layton, Rocuzzo, Heitz-Mayfield, 2018; Rocuzzo, Pittoni, Rocuzzo, Charrier, Dalmaso, 2017; Roos-Jansåker et al. 2014; Serino, Turri, Lang, 2015). The stability of clinical improvements following surgical treatments of peri-implantitis has been demonstrated in studies with varying supportive care intervals (Rocuzzo et al., 2017; Roos-Jansåker et al. 2014; Schwarz, Derks, Monje, Wang HL., 2018; Schwarz, Sahm, Bieling, Becker., 2009). The present study aimed to assess the long-term efficacy (follow-up: 5 years) of reconstructive treatment of peri-implantitis intraosseous defects using either autogenous bone graft or a bovine-derived xenograft combined with a resorbable membrane in patients attending a maintenance programme at three-month intervals.

2 | MATERIALS AND METHODS

2.1 | Study population

The Regional Ethics Committee in Lund, Sweden, approved the study (ID nr108/2007). All participating individuals signed informed consent. In addition, the CONSORT guidelines for clinical trials were followed. The study flow chart is presented (Figure 1).

The present study reports on the long-term outcomes of a study population of 45 patients diagnosed with peri-implantitis, surgically treated between 2007 and 2011 at a specialist centre in Uppsala, Sweden (Uppsala Käkkirurgiska Centrum). The one-year results have previously been reported (Aghazadeh et al., 2012). All patients attended a three-month maintenance programme during the study period of 5 years.

2.2 | Inclusion criteria

- I ≥ 1 osseointegrated implant with radiographic evidence of bone loss ≥ 2 mm, between the time of placement of the supra-structure and screening for study enrolment.
- II Probing pocket depth ≥ 5 mm combined with BOP/suppuration on probing.
- III Angular peri-implant bone defect (≥ 3 mm in depth as determined from intra-oral digital radiographs).

2.3 | Exclusion criteria

- I uncontrolled diabetes mellitus (HbA1c > 46 mmol/mol)
- II requiring antibiotic prophylaxis
- III taking prednisone or other anti-inflammatory medications
- IV using antibiotics in the preceding 3 months
- V taking medications known to affect gingival growth

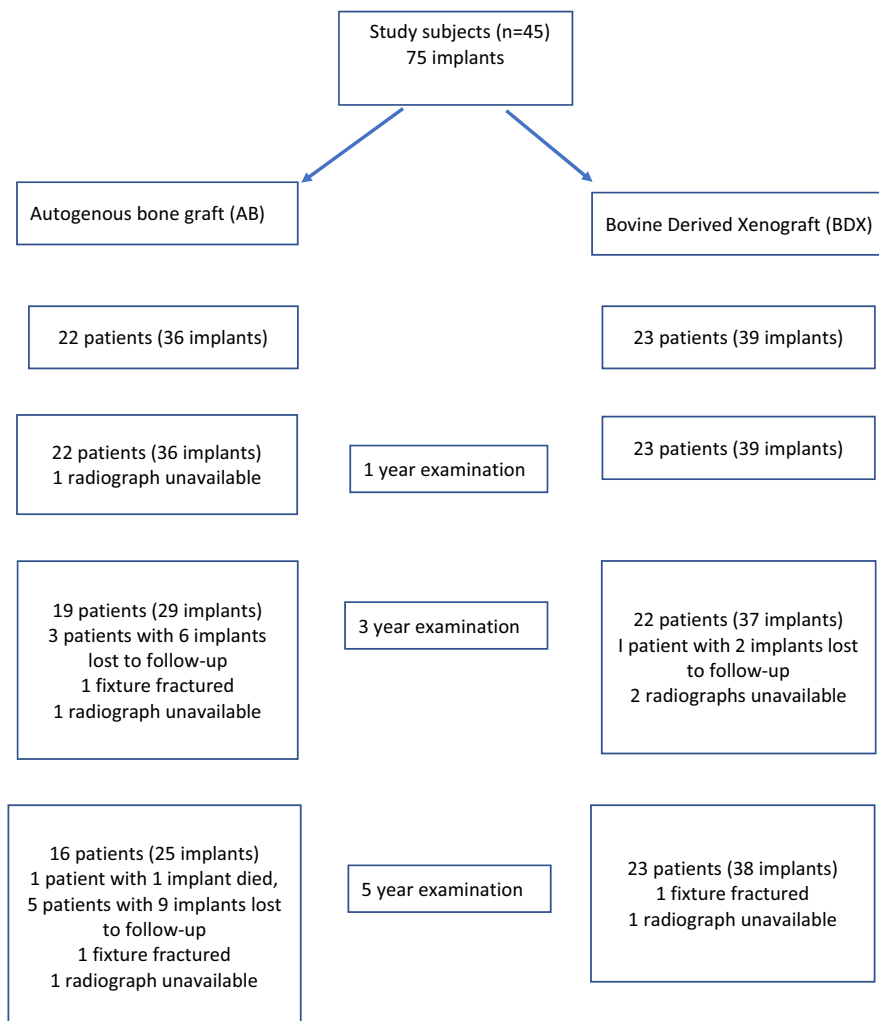
2.4 | Pre-treatment procedures

The participants' medical and dental histories were updated annually. Before enrolment, the study participants received periodontal therapy eliminating periodontal pockets > 5 mm at existing teeth. Implants diagnosed with inflammation (peri-implantitis) were treated non-surgically with titanium curettes and ultrasonics. Before the surgical procedure, the participants' oral hygiene was defined as being under control.

2.5 | Radiographic analysis

Standardized intra-oral radiographs were obtained using an Eggen holder and a long cone-equipped dental X-ray unit. At baseline, a complete set of intraoral radiographs were obtained unless recent radiographs taken within the last 3 months were available. New intra-oral radiographs were obtained following one, three and 5 years. Pre- and postoperative radiographs presenting the study implants were digitalized, coded and evaluated using a computer program (OsiriX Imaging software 3.9 for MAC OS 10.6, Osirix Foundation, Geneva, Switzerland). The mesial and distal distances from the implant platform to the bottom of the osseous defect were measured on radiographs taken at baseline, 1, 3 and 5 years. The one-year data have been reported previously (Aghazadeh, Person, Renvert., 2012). One calibrated examiner (GRP) who was masked to study allocation assessed all radiographs. The most coronal confluent aggregation of bone or bone-like material was used to define the marginal bone level. Single strands or islets of bone or bone-like material were not considered. Radiographs/measurements were calibrated based on the known distance between implant threads (Figure 2). Changes in bone levels (mean values of mesial and distal assessments) were

FIGURE 1 Study flow chart



calculated. Measurements of bone levels at radiographs at BL, years three and five, were compared. An improvement suggests radiographic evidence of bone gain.

2.6 | Clinical measurements and procedures

Unaware of the treatment group assignment, one experienced examiner (U.L.) performed all clinical examinations.

The following clinical data were registered at baseline, 1, 3 and 5 years after therapy:

- *Full mouth plaque score (PI)*, as presence/absence of plaque along the gingival/mucosal margin after use of disclosing dye (Top Dent, Lifco Dental AB, Enköping, Sweden) and expressed as a percentage of examined sites (4 sites/tooth and 4 sites/implant) with evidence of staining.
- *Local plaque score*, as presence/absence of plaque along the mucosal margin of each treated implant (4 sites/implant) after using the disclosing dye and expressed as a percentage of study implant sites with evidence of staining in each patient.

- *Probing pocket depth (PPD)* at the implants (4 sites/implant) and recorded to the nearest 1 mm using a plastic periodontal probe (Colorview, Hu-Friedy, Chicago, IL, USA).
- *Bleeding on probing (BOP)* was recorded as presence /absence of bleeding within 30s following probing at teeth and implants expressed as a percentage of examined sites.
- *Local BOP* at the study implant (4 sites/implant) was recorded as the presence/absence of BOP.
- *Suppuration (SUP)*, as the presence/absence of pus following probing (4 sites/implant).

2.7 | Surgical treatment

All implant-supported reconstructions were removed before surgical interventions. Local anaesthetics were administered, and following an intrasulcular incision, a mucoperiosteal flap was raised. Granulomatous tissues were removed, and the implant surfaces were debrided using titanium curettes (Deppeler SA, Rolle, Switzerland). Then, the implant surfaces were chemically cleaned with a gauze soaked in 3% hydrogen peroxide, followed

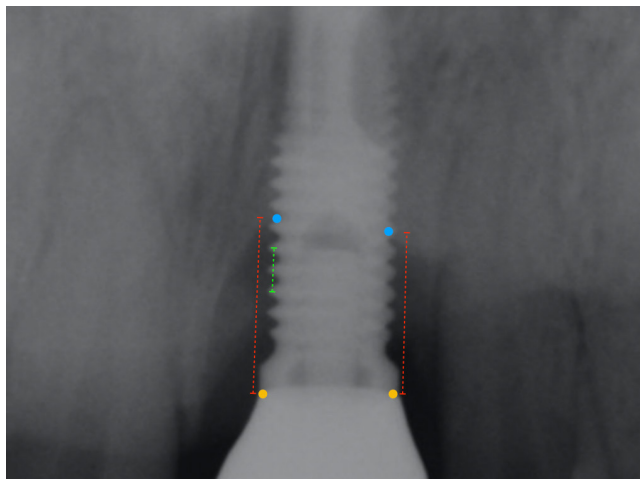


FIGURE 2 Illustration of the measurements on radiographs. The yellow points represent the implant-abutment junction, and the blue points the most coronal bone-to-implant contact. The red dotted lines represent the distance from the implant platform to the bottom of the defect. The green dotted line represents the distance between three threads used for calibration purposes

by thorough rinsing with saline. Assessments of defect characteristics, including the extent of bone loss/vertical defects from the implant platform to the most apical bone level, were made. The extent of bone loss/vertical defects from the implant platform to the most apical bone level and the distance from the implant platform to the most coronal part of the bone was measured (in mm) at the mesial, buccal, distal and lingual surfaces around the implant. In addition, the number of bone walls was assessed. These measurements were used to calculate the defect depth and to classify the defect as a 2-, 3- or 4-wall defect. The assignment to a treatment group was made using pre-prepared randomization in groups AB or BD. Simple randomization was performed using SPSS 18.0 software (IBM SPSS, Armonk, NY). Cards with group identification were prepared and placed in number-coded opaque and sealed envelopes. The randomization list was kept in a safe and not revealed to the investigators until data analyses had been performed. The treating clinician was unaware of the randomized treatment until the debridement of the defect was completed and the envelope with the code was opened.

Depending on the assignment, the defect was either filled with cortical AB obtained with a bone scraper (Safescraper® TWIST; Biomet3I Inc., Palm Beach, FL) or with BD (Bio-Oss® particle size 0.25-1.0 mm; Geistlich Pharma, Wolhusen, Switzerland) at the respective implant. In cases when AB could not be obtained in the surgical area, bone was harvested from the mandibular ramus region or the chin. A resorbable membrane (OsseoGuard®, Biomet3I Inc., Palm Beach, FL) was used to cover the AB or BD. The flaps were sutured using 4.0 sutures (Ethicon vicryl polyglactin, Johnson & Johnson, San Angelo, TX). All study participants were postoperatively prescribed antibiotics (Azithromycin 250 mg × 2 during Day one and then one tablet daily for 4 days). They also

received anti-inflammatory and analgesic medications (Ibuprofen 400 mg × 3 days) (Ibuprofen, Nycomed AB Stockholm, Sweden). In addition, the participants rinsed daily with 0.1% chlorhexidine (Hexident, Meda AB, Stockholm, Sweden) for 6 weeks.

Six weeks after surgery, the first supportive therapy was given. All participants were then placed on a maintenance programme with visits every third month. Plaque at implants was disclosed using an erythrosine dye (Top Dent Lifco Dental AB, Enköping, Sweden). Re-instructions in oral hygiene procedures were performed as deemed necessary. All existing teeth and implants were cleaned using a rubber cup and a low-abrasive paste. If BOP was detected during the maintenance visit, the area was re-instrumented with curettes (Deppeler SA, Rolle, Switzerland).

2.8 | Statistics

Statistical analysis included descriptive statistics for the clinical and radiographic parameters assessed at the implants at baseline, at years one, three and five. For the peri-implant and radiographic parameters, means and standard deviations were calculated. The study's primary outcome group was change in PPD. Radiographically assessed improvement of bone levels between baseline and radiographs obtained at 3 and 5 years was referred to as bone gain. As secondary outcomes bone gain and successful treatment outcome at year five, defined as no further radiographic evidence of bone loss between screening (BL) and year five, no presence of suppuration, no clinical finding of PPD > 5 mm and only one implant surface with BOP were used.

Statistical analyses were performed with independent t-tests (equal variance not assumed) and paired t-tests (equal variance not assumed), One-way ANOVA, chi-square (Pearson) and Mantel-Haenszel likelihood ratio. In addition, backwards conditional binary logistic regression analyses were performed to identify any association of gender, patient age, plaque scores at implants at baseline and 5 years, smoking, defect type or treatment assignment with treatment outcome. The reliability of the assessments was investigated by repeated measurements of bone levels on 15 radiographs using intra-class correlation (ICC). Statistical significance was determined at an alpha level of 0.05.

Data were analysed by the intention-to-treat principle (ITT), meaning that every randomized patient was included in the analysis using the last measurements available. In addition, data were also analysed for those patients remaining at the end of the five-year study, a per-protocol (PP) analysis.

The IBM SPSS 18 statistical software package for MAC computers was used for randomization, and IBM SPSS 27.0 was used for the other calculations (IBM, SPSS, Armonk, NY).

2.9 | Sample size calculation

We assumed a 0.4 mm probing pocket depth difference by group a standard deviation in PPD of 0.4 mm, and a normal distribution

pattern consistent with variation in the normal population. Twenty subjects in each group were required with $\alpha = 0.05$.

3 | RESULTS

Baseline study group conditions are presented as patient-based data (Table 1). At baseline, no differences in clinical measurements between study groups were identified. A summary of characteristics of the remaining study individuals and dental implants in the present study is presented in Figure 1. Twenty-two individuals with 36 dental implants with intraosseous defects classified as having ≥ 2 defect walls were included in the AB group. At year three, 19 individuals with 29 implants remained. One radiograph was unavailable leaving 28 implants for analysis of bone levels. At 5 years, 16 patients with 25 implants remained in the AB group. One radiograph was unavailable leaving 24 implants for analysis of bone levels. In the BDx group at year 3, 22 individuals with 37 dental implants were available. Two radiographs were unavailable leaving 35 implants for assessments of bone levels. At 5 years, 23 patients with 38 implants remained. One radiograph was unavailable leaving 37 implants for analysis of bone levels. Baseline study group conditions are presented as patient-based data (Table 1).

The mean age of study participants remaining at year five was 76.2 ± 6.7 (SD) years (range: 62–85) and 67.6 ± 7.3 (SD) years (range: 52–78) for the AB and BDx groups, respectively. Six individuals (35.8%) in the AB group and nine individuals (39.1%) in the BDx

group were smokers. Three wall defects were identified at 11 implants (44%) in the AB group and at 11 (29.7%) implants in the BDx group. Four wall defects were identified at three implants (12%) in the AB group and at five (13.5%) in the BDx group. Statistical analysis using independent t-tests failed to demonstrate differences between baseline osseous defect depths (mm) between turned and medium rough implant surfaces or by treatment procedures (AB or BDx). As defined at baseline, data analysis also failed to show differences in the distribution of implant type by defect configuration.

3.1 | Analyses of duplicate radiographic measurements

Repeated measurements of bone levels on radiographs were made of 29 implant surfaces. The ICC coefficient assessed from baseline radiographs based on single measures was 0.97 (95% CI 0.89, 0.98, $p < .001$). The ICC coefficient assessed from year one radiographs based on single measures was 0.76 (95% CI 0.42–0.59, $p < .001$).

3.2 | Patient-based full-mouth plaque and bleeding scores

This analysis included patients who completed the study in year 5. Data analysis failed to demonstrate statistical differences between

TABLE 1 Baseline study conditions patient data

Variables	AB group (n = 22)			BDx group (n = 23)		
	%	Mean	SD	%	Mean	SD
Gender (female)	63.6			56.5		
Subject age		70.1	6.2		67.0	7.5
Number of estimated packs/years (smokers only)		23.2	13.4		18.8	11.0
The proportion of edentulous subjects	13.6			26.1		
Number of remaining teeth in dentate subjects		13.4	7.4		12.9	7.8
Number of implants present		5.4	2.2		6.2	2.9
Number of implants with distance ≥ 2 mm from implant platform to bone level (implants in study)		3.4	1.7		3.6	2.2
Number of implants included in the study		1.7	0.7		2.1	1.4
Implant surface	Turned	14		19		
	Medium rough	22		20		

Note: Mean values, standard deviation (SD), standard error (SE) for group diff, 95% confidence intervals, and significance level for differences between study groups (equal variance not assumed). Included are values representing the autologous group (AB) and bovine graft derivate group (BDx), also including mean values for implant pocket probing depths (PPD), implant % surfaces with bleeding on probing (BOP) and bone level changes between baseline and year three, and between baseline and year five. When changes (with improvements in the BDx group, positive scores are recorded regarding SE diff and 95% CIs).

Abbreviations: AB, autogenous bone graft; BDx, bovine-derived xenograft.

study groups at all time points. The analysis also failed to demonstrate differences by study groups regarding the extent of changes for full-mouth PI and BOP scores over time. Study group mean PI and BOP scores with 95% confidence intervals are presented (Figures 3 and 4). PI and BOP scores decreased significantly between baseline and year 1, baseline and year 3, and between baseline and year 5 (p values varying between .01 and .001).

3.3 | Clinical and radiographic changes between baseline and years three and five in the AB group (pairwise assessments between baseline and years 3, versus 5) implant level assessments

The paired mean differences in implant mean BOP scores between baseline and year three and between baseline and year five were 50.7% and 55.6%, respectively ($p < .001$). Mean PPD levels were calculated at each implant and used for comparisons. The mean PPD level change at implant level between baseline and year three was 1.6 mm (SE mean 0.3 mm, 95% CI: 1.1, 2.2, $p < .001$), and 1.7 mm between baseline and year five (SE mean, 0.4, 95% CI: 1.1, 2.5, $p < .001$).

The mean bone level change at implant level between baseline and year three was -0.2 mm (SE mean 0.4 mm, 95% CI: -0.9, 0.6, NS), and -0.7 mm between baseline and year five (SE mean, 1.5, 95% CI: -1.6, 0.2, NS). An improvement suggesting radiographic evidence of bone gain between baseline and year five was only identified at five implants in the AB group.

3.4 | Clinical and radiographic changes between baseline and years three and five in the BDx group (pairwise assessments between baseline and years 3, versus 5) implant level assessments

The paired mean differences in implant mean BOP scores between baseline and year three and between baseline and year five were 50.6% and 50.6% respectively, ($p < .001$). The mean PPD level change at implant level between baseline and year three was 3.0 mm (SE mean 0.3 mm, 95% CI: 2.4, 3.5, $p < .001$) and 2.8 mm (SE mean, 0.3, 95% CI: 2.3, 3.4, $p < .001$).

The mean bone level change at implant level between baseline and year three was 1.6 mm (SE mean 0.3, 95% CI: 1.1, 2.2, $p < .001$), and was between baseline and year five 1.6 mm (SE mean, 0.3, 95% CI: 1.0, 2.2, $p < .001$). An improvement suggesting radiographic evidence of bone gain between baseline and year five was identified at 24 implants in the BDx group.

3.5 | Clinical and radiographic changes between study groups implant-based data (per-protocol)

Changes in BOP scores between baseline to year three and between baseline to year five were similar between the groups

(Table 2). However, significant study group differences were observed for PPD and bone level changes. Between baseline and year three and between baseline and year five, the decrease in PPD was more significant in the BDx group than in the AB group ($p < .001$).

Changes in radiographic evidence of bone level change in the AB group suggested continuing bone loss in contrast to the BDx group. These differences were statistically significant ($p < .001$). No difference in treatment outcomes defined by bone level changes in both study groups (baseline to 5 years) was observed between turned and medium rough implant surfaces.

3.6 | Successful treatment outcome after five years, implant-based comparisons (per-protocol analyses)

A successful treatment (no evidence of bone loss, no PPD > 5 mm, no suppuration, BOP at no more than one implant surface) was obtained in 9/25 (36%) implants in the AB group and 29/37 (78.3%) implants in the BDx group (Pearson's chi-square: 11.3, $p < .001$). Analysis by Mantel-Haenszel common odds estimate identified a likelihood of 6.4 (95% CI: 2.1, 20.0, $p < .001$). If a successful treatment outcome was required to include a gain in bone levels ≥ 1.0 mm and including the same criteria as above for suppuration, BOP and PPD, 5/25 (20%) implants in the AB group and 20/37 (54%) in the BDx were considered successfully treated (Pearson's chi-square: 5.0, $p < .05$). Analysis by Mantel-Haenszel common odds estimate identified a likelihood of 3.5 (95% CI: 1.1, 10.9, $p < .05$).

3.7 | Patient-based data (per-protocol)

Using the per-protocol principle, comparing patient-based data (mean values for those with ≥ 2 implants) and values for those with single implants (in all cases assessed based on a mean of mesial and distal readings) and identifying the primary outcome in the AB and BDx groups defined as a change in bone levels over the study period are presented (Table 3). A loss of bone was found in the AB group, whereas bone gain was observed in the BDx group. The difference between study groups was 1.5 mm at year three (SE diff: 0.6, 95% CI: 0.3, 2.6, $p < .01$) and 1.8 mm at year five (SE diff 0.6, 95% CI 0.6, 3.1, $p < .01$). At year five, 50% of the study patients in the AB group had a mean loss of bone ≥ 1.0 mm or more, whereas only one study individual in the BDx group had experienced a bone loss of ≥ 1.0 mm whereas 59% of the individuals in the BDx group presented with a bone gain of at least 1.0 mm.

3.8 | Radiographic changes between study groups (intention- to- treat)

Study group differences when the intention-to-treat (ITT) protocol was used for changes in bone levels over time are presented

FIGURE 3 Mean full mouth plaque score at BL, 1, 3 and 5 years for patients that completed the study

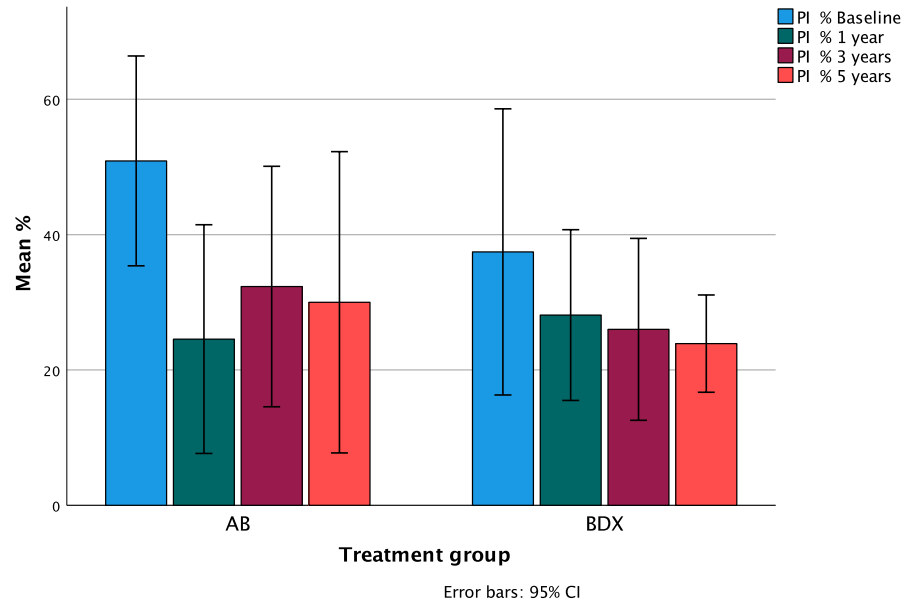
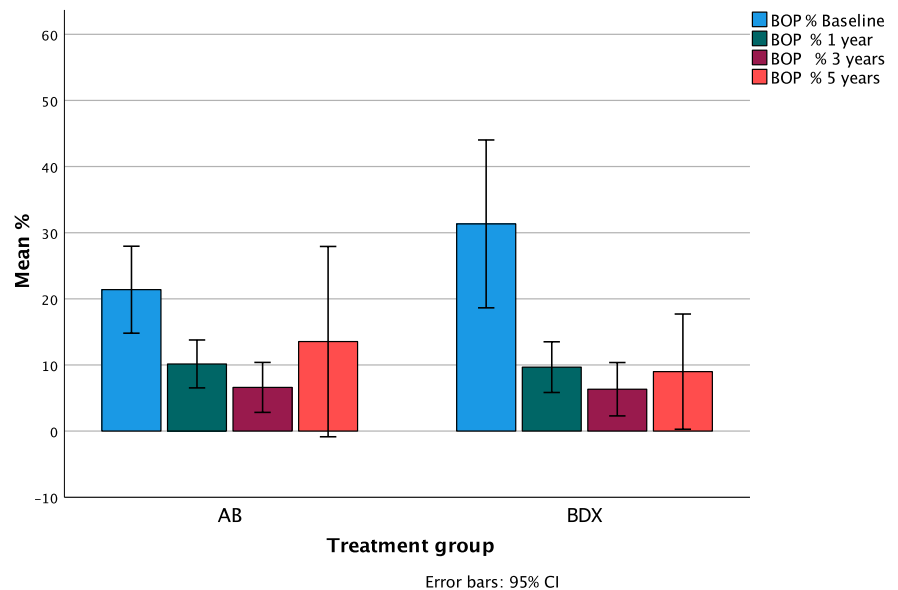


FIGURE 4 Mean full mouth BOP at BL for 1, 3 and 5 years for patients that completed the study



(Table 4). In the BDX group, bone gain was observed at three and 5 years, whereas bone loss was registered at 5 years in the AB group. In addition, in the BDX group at 5 years, only 3/37 (8%) implants had experienced bone loss ≥ 1 mm. In contrast, 17/25 (68%) in the AB group experienced a bone loss ≥ 1 mm at year five.

4 | DISCUSSION

The present study assessed treatment outcomes of two reconstructive surgical procedures using either AB or BDX as the augmentation material. The patients were enrolled in a maintenance care programme with visits every third month following the initial therapy. The present study demonstrated that long-term bone level gains following reconstructive therapy using BDX as an augmentation material are possible. These results are in accordance with previously

published long-term data on reconstructive therapy of intraosseous defects at dental implants using a xenograft (Roccuzzo, Pittoni, Roccuzzo, Charrier, Dalmaso., 2017, Roccuzzo, Fierravanti, Pittoni, Dalmaso, Roccuzzo., 2020), or a combination deproteinized bovine bone mineral with 10% collagen (DBBMC), enamel matrix derivative (EMD) and Doxycycline (Mercado, Hamlet, Ivanovski., 2018). In addition, the amount of bone gain obtained in the BDX group in the present study was in line with five-year follow-up results following reconstructive therapy reported by Roos-Jansåker et al. (2014) using a coral-based bone substitute (Algipore, Friadent, Malmö, Sweden).

One year after surgery, a bone gain of 1.1 mm was reported in the BDX group and 0.2 mm in the AB group (Aghazadeh, Person, Renvert., 2012). However, the initial bone gain found in the AB group was lost over time, whereas a further bone gain was noted in the BDX group at 5 years. AB placed in the defects at BL was probably resorbed, indicating bone loss. In contrast, the placement

TABLE 2 Per protocol: Implant-based data including the number of observations

Variable	AB group			BDX group			SE diff	95% CI lower upper	Sign
	N	Mean	SD	N	Mean	SD			
Bleeding on probing % change (positive scores = improvements)									
BOP change baseline to 3 year-examinations	29	50.7	34.0	37	50.6	45.0	4.6	-18.0, 18.5	NS
BOP change baseline to five-year examinations	25	55.6	32.8	38	50.6	44.9	0.21	-19.1, 18.9	NS
Probing pocket depth decrease (mm) (positive scores = improvements)									
PPD level change baseline to 3 years examinations	29	1.6	1.5	37	3.0	1.6	1.5	0.7, 2.1	0.001
PPD level change baseline to 5 years examinations	25	1.7	1.8	38	2.8	1.7	1.1	0.2, 2.0	0.001
Bone level change (mm); positive value = decrease in depth (gain), negative value = increase in distance (loss)									
Bone level change baseline to 3 years examinations	28	-0.2	1.8	35	1.6	1.6	1.8	0.9, 2.6	0.001
Bone level change baseline to 5 years examinations	24	-0.7	1.5	37	1.6	1.8	0.5	1.2 3.2	0.001

Abbreviations: AB, autogenous bone graft; BDX, bovine-derived xenograft; BOP, bleeding on probing; PPD, probing pocket depth.

TABLE 3 Per-protocol: Patient-based data bone level change between baseline and years 3 and 5.

Variable	AB group			BDX group			SE diff	95% CI	Sign
	N	Mean	SD	N	Mean	SD			
Bone level change baseline to year three examination	19	-0.1	1.8	22	1.4	1.6	0.6	0.3, 2.6	0.01
Bone level change baseline to year five examination	16	-0.2	1.8	22	1.6	1.9	0.6	0.6, 3.1	0.01

Abbreviations: AB, autogenous bone graft; BDX, bovine-derived xenograft.

TABLE 4 Intention to treat (ITT)

Variable	AB group			BDX group			SE diff	95% CI lower, upper	Sign
	N	Mean	SD	N	Mean	SD			
Implant-based analyses									
Bone level change baseline to three-year examinations	36	0.0	1.8	39	1.7	1.6	0.93	1.0, 2.5	0.001
Bone level change baseline to five-year examinations	36	-0.3	1.6	39	1.6	1.8	0.4	1.1, 2.7	0.001

Note: Implant-based data including the number of observations, mean values, standard deviation (SD), standard error (SE) for group diff, 95% confidence intervals and significance level for study group differences (equal variance not assumed). Values representing the autologous group (AB) and bovine graft derivate group (BDX) are included. Due to failure to assess bone levels or loss to follow-up, the ITT analyses using bone level data from preceding recordings.

Abbreviations: AB, autogenous bone graft; BDX, bovine-derived xenograft.

of a xenograft may have initiated new bone formation, resulting in a radiographically assessed bone gain. The present study used two different definitions of a successful treatment outcome. Regardless of definition, a more successful treatment outcome was found in the BDX group than the AB group.

The importance of maintenance visits to prevent/reduce the incidence of peri-implantitis has been highlighted (Roos-Jansåker, Lindahl, Persson, Renvert., 2011, Rocuzzo, De Angelis, Bonino, Aglietta., 2010, Rinke, Ohl, Ziebolz, Lange, Eickholz., 2011,

Costa et al. 2012, Pjetursson et al. 2012, Serino et al. 2015, Monje et al. 2016, Monje, Wang, Nart., 2017, Hu, Lang, Ong, Lim, Tan., 2020). Frequent maintenance visits may be critical for maintaining initially obtained treatment results. In the present study, similar to Roos-Jansåker et al. (2014), all patients attended a 3-month maintenance programme. Despite frequent maintenance visits every third month in the present study, loss of bone was observed in the AB group, whereas in the BDX group, an additional bone gain was observed at three and 5 years. Sixty-eight per cent of the implants

in the AB group and 8% of the implants in the BDX group presented with bone loss ≥ 1 mm at 5 years. In a study by Carcuac et al. (2020) using a resective surgical approach, 44% of the remaining implants was diagnosed with the progression of peri-implantitis, which occurred even though the patients had been monitored regularly. Disease recurrence may be related to disease severity at baseline, the initial treatment or the choice of augmentation material. In a recent publication evaluating the results of resective treatment of peri-implantitis, Ravidá et al. (2020) demonstrated that the probability of implant failure was influenced by the extent of the marginal bone loss at baseline. We can only speculate that the positive outcome in the BDX group may be related to the use of an augmentation material that was not resorbed and remained in the defects. In the present study, pocket depths were reduced in both groups. However, PPD values were more reduced in the BDX group than in the AB group. The more pronounced reduction in PPD in the BDX group may be related to bone gain. In contrast, the reduction in PPD in the AB group may primarily result from soft tissue retraction.

An important shortcoming of the present study is that several individuals in the AB group were lost to follow-up. Ten dental implants (28%) were lost to follow-up and one implant was fractured in the AB group. However, the percentage of implants lost to follow-up in the AB group is similar to what has been reported in another recent long-term follow-up study after resective peri-implantitis surgery in which 27% of implants were lost to follow-up (Carcuac et al., 2020). Loss to follow-up is a problem with long-term studies evaluating treatment of peri-implantitis as many of the treated individuals are old. In the present study, the mean age of the individuals at baseline in the AB group was over 70 years, and general health issues may account for the loss of follow-up. The review of case history, age, gender and other clinical factors could, however, not explain the loss to follow-up in the AB group. Whether the implants lost to follow-up in the present study were associated with bone loss could not be further investigated. Notwithstanding, bone loss was observed in the AB group at 5 years, even when the ITT principle was used for the analysis. Thus, both data from the ITT analysis and the per-protocol analysis point in the same direction favouring the use of BDX as augmentation material in intraosseous defects at dental implants.

It should be acknowledged that analyses of bone level changes assessed from radiographs of sites grafted with radio-opaque materials (as in the case of DBX) only indicate the possibility of reconstruction of alveolar bone in 2-, 3- or 4-wall defects. The assessment methods used in the present study cannot define whether the bone gain is of functional value. This is also in part illustrated by the differences in ICC single measures values between baseline and year one radiographs. One explanation might be radiopaque material that could be difficult to define as residuals of bone grafting material or actual bone. It should also be recognized that assessments from radiographs are substitute measures while invasive surgical re-entry procedures were not warranted.

It should be acknowledged that despite all patients attending the maintenance visits, the BOP values were higher than the PI, indicating that the patients improved their oral hygiene just before

the maintenance visits. Other limitations of the study include the lack of information on soft tissue dehiscence and the number of re-instrumentations during the follow-up period. There is also a potential imprecision of data analysis due to the lack of adjustment for clustering and the lack of calibration for the PPD as another study limitation.

In conclusion, reconstructive surgical treatment of peri-implant defects using BDX resulted in more predictable outcomes than using autogenous bone over 5 years.

AUTHOR CONTRIBUTIONS

Ahmad Aghazadeh: Formal analysis (equal); investigation (lead); methodology (equal); project administration (lead); writing – original draft (lead). **Rutger G. Persson:** Formal analysis (lead); investigation (equal); supervision (equal); writing – review and editing (equal). **Andreas Stavropoulos:** Formal analysis (equal); supervision (equal); writing – review and editing (equal). **Stefan Renvert:** Conceptualization (lead); formal analysis (equal); funding acquisition (lead); methodology (equal); supervision (equal); writing – review and editing (equal).

ACKNOWLEDGEMENTS

We appreciate the support for the study from the University of Kristianstad, Sweden and the Uppsala Käkkirurgiska Center, and Ms Ulla Lundström RDH (UL) for the clinical measurements.

FUNDING INFORMATION

Biomet 3I funded the initial 12-month study. The long-term follow-up was self-funded by the authors and their institution.

CONFLICT OF INTEREST

Drs. Aghazadeh, Persson and Stavropoulos have nothing to disclose. Dr. Renvert reports grants from Biomet 3i, during the conduct of the study; grants and personal fees from Geistlich Pharma AG, outside the submitted work.

DATA AVAILABILITY STATEMENT

The data that support the findings of this study are available from the corresponding author, [SR], upon reasonable request

ETHICS STATEMENT

This material is the authors' original work, which has not been previously published elsewhere.

ORCID

G. Rutger Persson  <https://orcid.org/0000-0002-7976-3849>

Andreas Stavropoulos  <https://orcid.org/0000-0001-8161-3754>

Stefan Renvert  <https://orcid.org/0000-0003-0992-2362>

REFERENCES

Aghazadeh, A., Persson, G. R., & Renvert, S. (2012). A single-centre randomized controlled clinical trial on the adjunct treatment of intra-bony defects with autogenous bone or a xenograft: results after 12

- months. *Journal of Clinical Periodontology*, 39, 666–673. <https://doi.org/10.1111/j.1600-051X.2012.01880.x>
- Berglundh, T., Armitage, G., Araujo, M. G., Avila-Ortiz, G., Blanco, J., Camargo, P. M., Chen, S., Cochran, D., Derks, J., Figuero, E., Hämmeler, C. H. F., Heitz-Mayfield, L. J. A., Huynh-Ba, G., Iacono, V., Koo, K. T., Lambert, F., McCauley, L., Quirynen, M., Renvert, S., ... Zitzmann, N. J. (2018). Peri-implant diseases and conditions: Consensus report of workgroup 4 of the 2017 World Workshop on the Classification of Periodontal and Peri-Implant Diseases and Conditions. *Journal of Clinical Periodontology*, 45(20), S286–S291.
- Carcuac, O., Derks, J., Abrahamsson, I., Wennström, J. L., & Berglundh, T. (2020). Risk for recurrence of disease following surgical therapy of peri-implantitis—A prospective longitudinal study. *Clinical Oral Implants Research*, 31(11), 1072–1077. <https://doi.org/10.1111/clr.13653>
- Clem, D., & Gunsolley, J. C. (2019). Peri-implantitis Treatment Using Er: YAG Laser and Bone Grafting. A Prospective Consecutive Case Series Evaluation: 1 Year Posttherapy. *International Journal of Periodontics and Restorative Dentistry*, 39, 479–489. <https://doi.org/10.11607/prd.4158>
- Costa, F. O., Takenaka-Martinez, S., Cota, L. O. M., Ferreira, S. D., Silva, G. L. M., & Costa, J. E. (2012). Periimplant disease in subjects with and without preventive maintenance: a 5-year follow-up. *Journal of Clinical Periodontology*, 39, 173–181. <https://doi.org/10.1111/j.1600-051X.2011.01819.x>
- Derks, J., & Tomasi, C. (2015). Peri-implant health and disease. A systematic review of current epidemiology. *Journal of Clinical Periodontology*, 42, S158–S171. <https://doi.org/10.1111/jcpe.12334>
- Heitz-Mayfield, L. J. A., Salvi, G. E., Mombelli, A., Loup, P. J., Heitz, F., Kruger, E., & Lang, N. P. (2018). Supportive peri-implant therapy following anti-infective surgical peri-implantitis treatment: 5-year survival and success. *Clinical Oral Implants Research*, 29, 1–6. <https://doi.org/10.1111/clr.12910>
- Hu, C., Lang, N. P., Ong, M. M.-A., Lim, L. P., & Tan, W. C. (2020). Influence of periodontal maintenance and periodontitis susceptibility on implant success: A 5-year retrospective cohort on moderately rough-surfaced implants. *Clinical Oral Implants Research*, 31, 727–736. <https://doi.org/10.1111/clr.13621>
- Jepsen, K., Jepsen, S., Laine, M. L., Anssari, M. D., Pilloni, A., Zeza, B., Sanz, M., Ortiz-Vigón, A., Roos-Jansäker, A. M., & Renvert, S. (2016). Reconstruction of Peri-implant Osseous Defects: A Multicenter Randomized Trial. *Journal of Dental Research*, 95, 58–66.
- Mercado, F., Hamlet, S., & Ivanovski, S. (2018). Regenerative surgical therapy for peri-implantitis using deproteinized bovine bone mineral with 10% collagen, enamel matrix derivative and Doxycycline-A prospective 3-year cohort study. *Clinical Oral Implants Research*, 29, 583–591.
- Monje, A., Aranda, L., Diaz, K. T., Alarcon, M. A., Bagramian, R. A., Wang, H. L., & Catena, A. (2016). Impact of maintenance therapy for the prevention of peri-implant diseases: A systematic review and meta-analysis. *Journal of Dental Research*, 95(4), 372–379. <https://doi.org/10.1177/0022034515622432>
- Monje, A., Wang, H. L., & Nart, J. (2017). Association of Preventive Maintenance Therapy Compliance and Peri-Implant Diseases: A Cross-Sectional Study. *Journal of Periodontology*, 88, 1030–1041. <https://doi.org/10.1902/jop.2017.170135>
- Nart, J., de Tapia, B., Pujol, À., Pascual, A., & Valles, C. (2018). Vancomycin and tobramycin impregnated mineralized allograft for the surgical regenerative treatment of peri-implantitis: a 1-year follow-up case series. *Clinical Oral Investigations*, 22(6), 2199–2207. <https://doi.org/10.1007/s00784-017-2310-0>
- Pjetursson, B. E., Helbling, C., Weber, H.-P., Matuliene, G., Salvi, G. E., Brägger, U., & Lang, N. P. (2012). Peri-implantitis susceptibility as it relates to periodontal therapy and supportive care. *Clinical Oral Implants Research*, 23, 888–894. <https://doi.org/10.1111/j.1600-0501.2012.02474.x>
- Ravidà, A., Siqueira, R., Saleh, I., Saleh, M. H. A., Giannobile, A., & Wang, H. L. (2020). Lack of Clinical Benefit of Implantoplasty to Improve Implant Survival Rate. *Journal of Dental Research*, 99, 1348–1355. <https://doi.org/10.1177/0022034520944158>
- Renvert, S., Roos-Jansäker, A. M., & Claffey, N. (2008). Non-surgical treatment of peri-implant mucositis and peri-implantitis: a literature review. *Journal of Clinical Periodontology*, 35, 305–315. <https://doi.org/10.1111/j.1600-051X.2008.01276.x>
- Renvert, S., Roos-Jansaker, A. M., & Persson, G. R. (2018). Surgical treatment of peri-implantitis lesions with or without the use of a bone substitute—a randomized clinical trial. *Journal of Clinical Periodontology*, 45, 1266–1274. <https://doi.org/10.1111/jcpe.12986>
- Rinke, S., Ohl, S., Ziebolz, D., Lange, K., & Eickholz, P. (2011). Prevalence of peri-implant disease in partially edentulous patients: a practice-based cross-sectional study. *Clinical Oral Implants Research*, 22, 826–833. <https://doi.org/10.1111/j.1600-0501.2010.02061>
- Roccuzzo, M., de Angelis, N., Bonino, L., & Aglietta, M. (2010). Ten-year results of a three arms prospective cohort study on implants in periodontally compromised patients. Part 1: implant loss and radiographic bone loss. *Clinical Oral Implants Research*, 21, 490–496. <https://doi.org/10.1111/j.1600-0501.2009.01886>
- Roccuzzo, M., Fierravanti, L., Pittoni, D., Dalmaso, P., & Roccuzzo, A. (2020). Implant survival after surgical treatment of peri-implantitis lesions by means of deproteinized bovine bone mineral with 10% collagen: 10-year results from a prospective study. *Clinical Oral Implants Research*, 31, 768–776. <https://doi.org/10.1111/clr.13628>
- Roccuzzo, M., Gaudio, L., Lungo, M., & Dalmaso, P. (2016). Surgical therapy of single peri-implantitis intrabony defects, by means of deproteinized bovine bone mineral with 10% collagen. *Journal of Clinical Periodontology*, 43, 311–318. <https://doi.org/10.1111/jcpe.12516>
- Roccuzzo, M., Layton, D. M., Roccuzzo, A., & Heitz-Mayfield, L. J. (2018). Clinical outcomes of peri-implantitis treatment and supportive care: A systematic review. *Clinical Oral Implants Research*, 29(16), 331–350. <https://doi.org/10.1111/clr.13287>
- Roccuzzo, M., Pittoni, D., Roccuzzo, A., Charrier, L., & Dalmaso, P. (2017). Surgical treatment of peri-implantitis intrabony lesions by means of deproteinized bovine bone mineral with 10% collagen: 7-year-results. *Clinical Oral Implants Research*, 28, 1577–1583. <https://doi.org/10.1111/clr.13028>
- Roos-Jansaker, A. M., Lindahl, C., Persson, G. R., & Renvert, S. (2011). Long-term stability of surgical bone regenerative procedures of peri-implantitis lesions in a prospective case-control study over 3 years. *Journal of Clinical Periodontology*, 38, 590–597. <https://doi.org/10.1111/j.1600-051X.2011.01729.x>
- Roos-Jansäker, A. M., Persson, G. R., Lindahl, C., & Renvert, S. (2014). Surgical treatment of peri-implantitis using a bone substitute with or without a resorbable membrane: a 5-year follow-up. *Journal of Clinical Periodontology*, 41, 1108–1114. <https://doi.org/10.1111/jcpe.12308>
- Roos-Jansäker, A. M., Renvert, H., Lindahl, C., & Renvert, S. (2007). Surgical treatment of peri-implantitis using a bone substitute with or without a resorbable membrane: a prospective cohort study. *Journal of Clinical Periodontology*, 34, 625–632. <https://doi.org/10.1111/j.1600-051X.2007.01102.x>
- Schwarz, F., Derks, J., Monje, A., & Wang, H. L. (2018). Peri-implantitis. *Journal of Periodontology*, 89(1), S267–S290. <https://doi.org/10.1002/JPER.16-0350>
- Schwarz, F., Sahn, N., Bieling, K., & Becker, J. (2009). Surgical regenerative treatment of periimplantitis lesions using a

nanocrystalline hydroxyapatite or a natural bone mineral in combination with a collagen membrane: a four-year clinical follow-up report. *Journal of Clinical Periodontology*, 36, 807–814. <https://doi.org/10.1111/j.1600-051X.2009.01443.x>

Serino, G., Turri, A., & Lang, N. P. (2015). Maintenance therapy in patients following the surgical treatment of peri-implantitis: A 5-year follow-up study. *Clinical Oral Implants Research*, 26(8), 950–956. <https://doi.org/10.1111/clr.12418>

How to cite this article: Aghazadeh, A., Persson, G. R., Stavropoulos, A., & Renvert, S. (2022). Reconstructive treatment of peri-implant defects—Results after three and five years. *Clinical Oral Implants Research*, 00, 1–11. <https://doi.org/10.1111/clr.13994>